



**RESEARCH RESULTS:  
THE EFFECTS OF USING  
MSTR®  
(McLOUGHLIN SCAR TISSUE RELEASE®)  
ON CAESAREAN SECTION  
SCARS**

Conducted on October 26th - 2019

at

The Newcastle Clinic  
4 Towers Avenue, Jesmond,  
Newcastle upon Tyne,  
NE2 3QE  
United Kingdom

## PRESS RELEASE

I am delighted to announce the results on the latest research study into the effects of McLoughlin Scar Tissue Release® (MSTR®) on Caesarean Section scars.

This second MSTR® research project was conducted at The Newcastle Clinic, Newcastle, UK on October 26th, 2019 with Consultant Radiologist Dr Peddada Raju MD.

A General Electric (GE) Soniq S8 ultrasound scanner was used to conduct the test on nine test subjects with C-section scars.

Each subject was pre-scanned and images recorded including:

- Size and depth of scar tissue
- The amount of vascularity both surrounding and within the scar tissue

MSTR® work was then applied for a total of 15 minutes per subject, as a single treatment.

Immediately after MSTR® treatment each subject underwent a post-treatment ultrasound scan conducted by Dr Raju.

All nine subjects were shown to have decreased scar tissue in the post treatment scan. One example of improvement was of a scar that was initially measured at 16.6mm pre treatment. The scar was re-measured at just 3.6mm post treatment.

Another example was that of a longitudinal scar reducing in size from 18.42mm pre-treatment to just 8.81mm post-treatment.

In several cases an increase in vascularity was noted, not only in the surrounding tissue but also actually through the scar. Interestingly it should be noted that in some instances NO vascularity was present in the pre-scan of the same area.

This second study re-confirms what was noted in the first study of June 15th, 2019: MSTR® not only reduces scar tissue but also helps release the densely bound collagen fibres that make up scar tissue to allow increased blood flow into the area once again.

You can read more about the MSTR® Research Project here:

<https://www.mcloughlin-scar-release.com/research/>

This second research project, demonstrating evidence-based outcomes of the MSTR® method of scar tissue treatment, reinforces and confirms our previous finding from June 2019 and means you can have even more confidence in the reliability and consistency of MSTR® work.

## **RESEARCH RESULTS**

### **Overview**

Of the nine scars we researched seven were transverse C-sections, one was abdominoplasty, one was abdominal hysterectomy.

### **Funding**

This research study was funded entirely by public and private contributions.

### **Research participants**

Research participants were found via social media requests.

The specific objectives for ultrasound imaging using MSTR® technique are:

- Changes in scar tissue size and depth
- Changes in blood flow (vascularity) in adjacent tissues surrounding the scar tissue
- Changes in blood flow (vascularity) within the scar tissue itself

### **The research team:**

Dr. Peddada Raju - Consultant Radiologist

Paula Esson - Research liaison, MSTR® practitioner and Dr Raju's assistant

Silke Lauth - Research assistant, MSTR® practitioner

Alastair McLoughlin - creator of MSTR®, lead practitioner

### **Venue:**

The Newcastle Clinic

4 Towers Avenue, Jesmond,

Newcastle upon Tyne,

NE2 3QE

United Kingdom

## **Hypothesis**

Due to the increasing evidence from hundreds of recorded case studies from a large variety of post-surgical and trauma wound scars that display extremely good and consistent changes in scar tissue, we hypothesise that these changes are due to the separation of the tightly bound collagen matrix and substrate found at scar tissue sites using the MSTR® method.

We hypothesise that blood and lymph flow increases through and around the scar tissue site.

The already observed surface changes in scar tissue density and fibrosis suggests the possibility that collagen fibres within scar tissue are re-aligned forming a more natural alignment - as found in healthy unaffected tissues.

We also hypothesise that adhered fascial structures surrounding the scar are also released.

Frequently, sensory changes and improvement in nerve transmission are also noted by case study feedback.

We also have case study evidence that Range-of-Motion tests indicate improved functionality of the spine and limbs. Changes and reduction in lower back pain for example may be another benefit of C-section treatment.

## **Method**

- We conducted the research study on nine subjects.
- A patient questionnaire was used to collect general information about the patient. We also included specific questions concerning the C-section itself: when the surgery took place, any physical effects the scar produces and any emotional or psychological effects that might be experienced because of the scar.
- A pre-treatment ultrasound scan was conducted by Dr Peddada Raju. Images were captured via GE Soniq S8 Ultrasound scanner. Scar tissue measurements were also recorded.
- MSTR® treatment was performed on the abdominal scar for 15 minutes in total. During the 15 minutes treatment, two breaks of two minutes each were included. This reduced actual MSTR® treatment to approximately 11 minutes hands-on time in total.
- A post treatment ultrasound scan and scar tissue measurements conducted by Dr Raju were recorded.



## Results

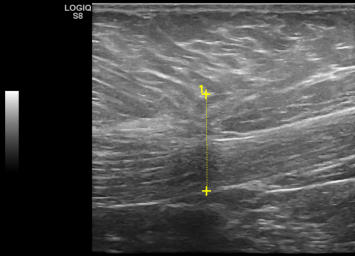


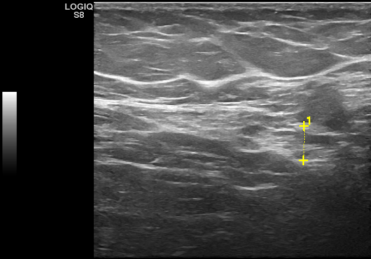
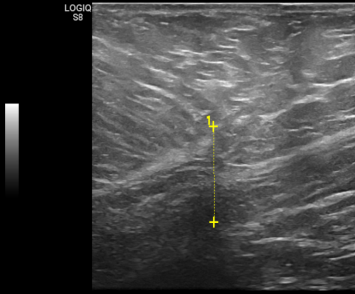
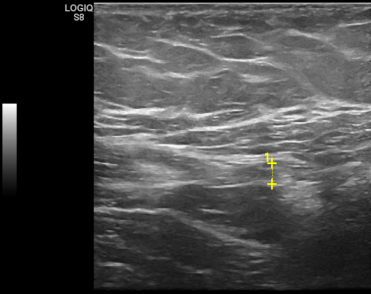
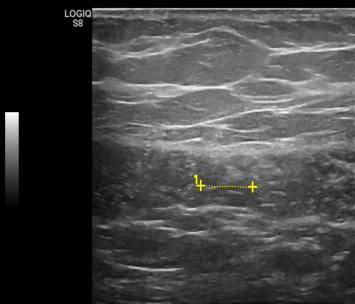
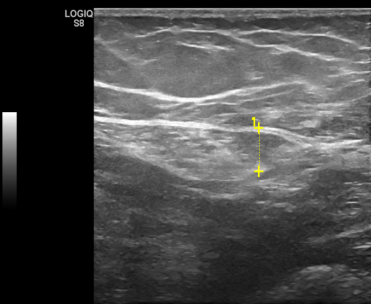
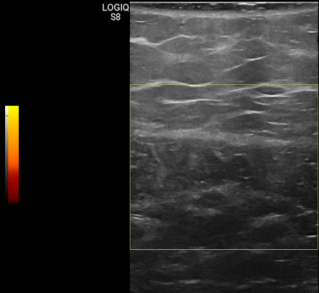
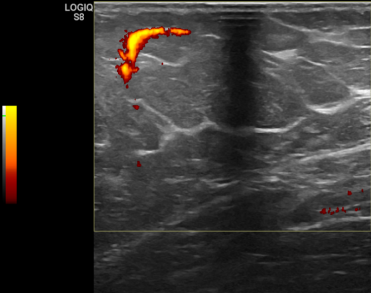
SUBJECT ID	DD	LF	NC	PE	CW	AB	KH	JC	SS
Age	46 y. 7mo.	37 y. 3 mo.	49 y. 1 mo.	49 y. 9 mo.	50 y. 3 mo.	53 y. 5 mo.	42 y. 1 mo.	36 y. 5 mo.	33 y. 7 mo.
Number of C - sections	2	1	1 abdominal hysterectomy	1	2	3	1	1 abdomino plasty	1
Age of C- sections	13 years + 11 years	5 months	3 years	23 years	20 years + 18 years	21 years, 18 years, 17 years	3 years	1 year	1 year
Type Emergency = E Planned =P	E+P	P	P	E	P+E	E+P+P	E	P	P
Values:									
Pre tx Deepest	19.3mm	14.21mm	11.35mm	*	19.15mm	17.12mm	7.05mm	10.14mm	9.3mm
Post tx Deepest	10.7mm	7.26mm	9.95mm	*	14.29mm	15.79mm	5.88mm	7.85mm	7.56mm
Pre tx Longitudinal	9.4mm	10.03mm	6.73mm	18.42mm	15.14mm	14.28mm	11.05mm	8.08mm	5.34mm
Post tx Longitudinal	6.7mm	5.28mm	6.55mm	8.81mm	8.4mm	8.25mm	10.77mm	7.62mm	4.86mm
Pre tx Deep	16.6mm	11.95mm	11.22mm	*	16.14mm	10.99mm	5.6mm	7.78mm	6.6mm
Post tx Deep	3.6mm	5.11mm	5.13mm	*	10.62mm	9.0mm	3.6mm	7.14mm	4.39mm
Pre tx Transverse	9.9mm	9.72mm	7.2mm	14.97mm	12.78mm	13.52mm	8.95mm	5.84mm	3.36mm**
Post tx Transverse	7.3mm	5.71mm	4.65mm	11.34mm	8.58mm	11.77mm	6.36mm	4.02mm	5.7mm**

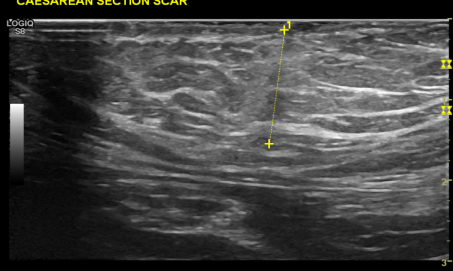

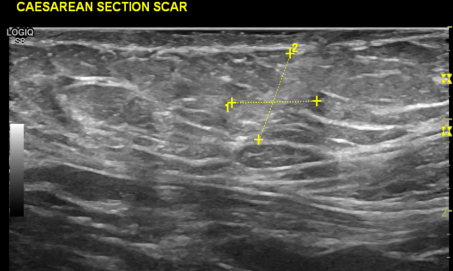
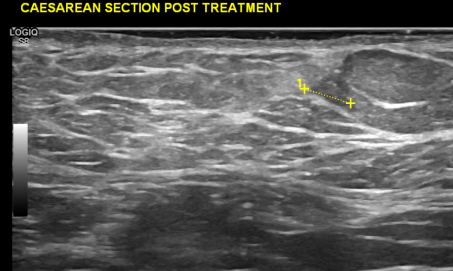
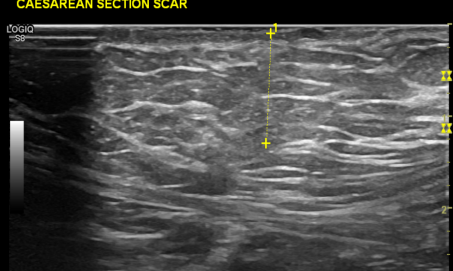
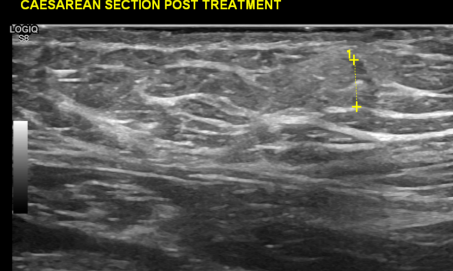
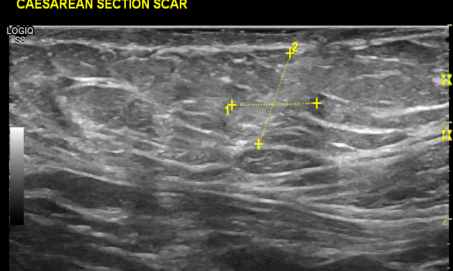
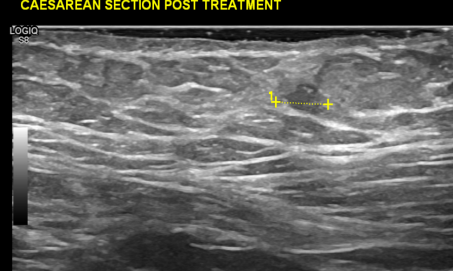
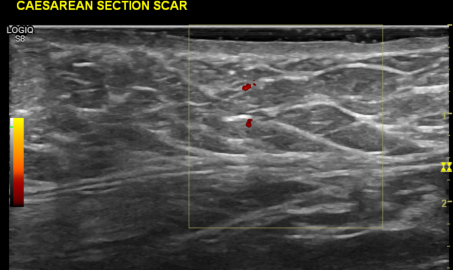

\* = Accurate measurements were not possible to be taken for these areas.

\*\* = A seemingly anomalous reading where scar tissue seemed to increase. The post treatment measurement was checked three times by Dr Raju to ensure accuracy. After consultation with Dr Raju we concluded that an increase in lymph fluid in the area may have been responsible for the apparent larger scar measurement. On the ultrasound image you can see two small black areas (fluid) pre treatment, which have disappeared in the post treatment image.

### TOTAL SCAR MEASUREMENTS AND PERCENTAGE OF CHANGE:

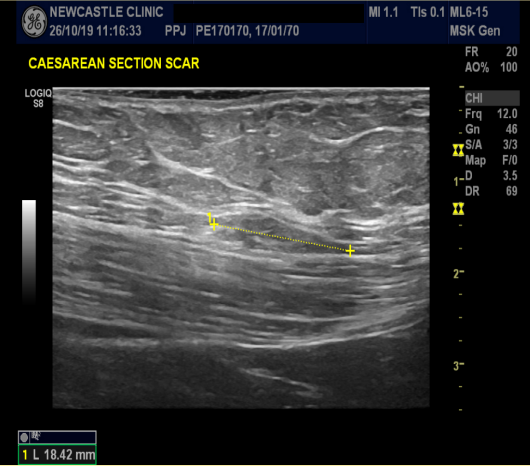
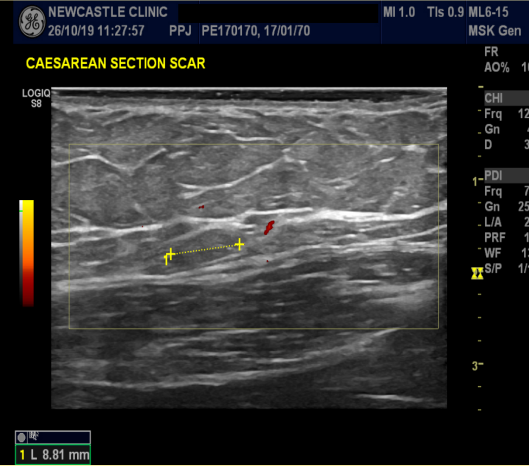
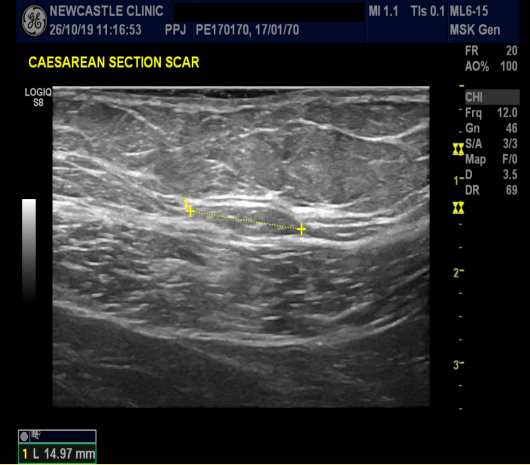
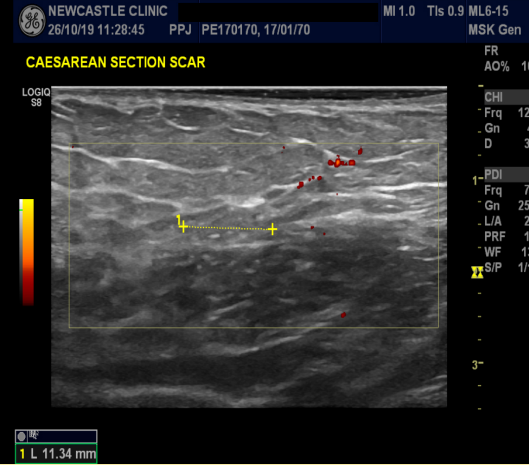
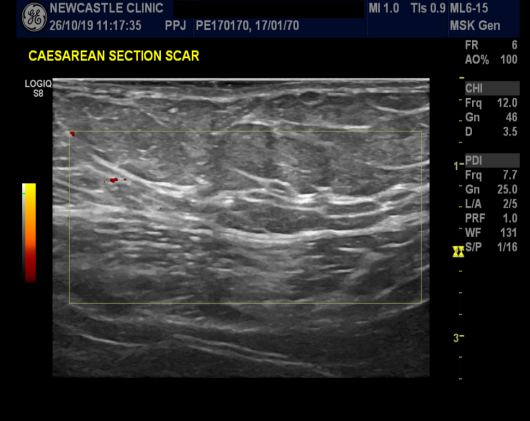
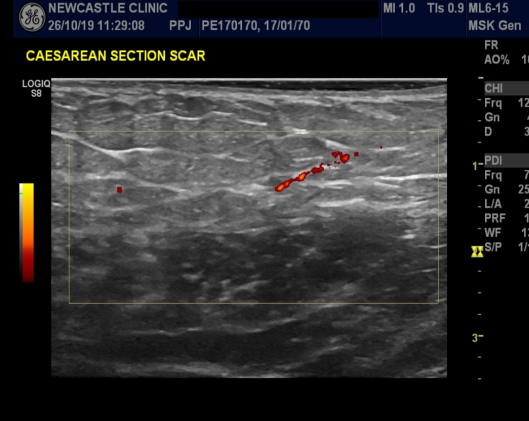
	Pre treatment	Post treatment	Percentage reduction
deepest	107.62mm	79.28mm	26.33%
longitudinal	98.47mm	67.24mm	31.72%
deep	86.88mm	48.59mm	44.07%
transverse	86.24mm	65.7mm	23.82%
Total measurements	379.21mm	260.81mm	31.22%

Subject DD	Pre treatment	Post treatment
deepest	<p>NEWCASTLE CLINIC 26/10/19 09:40:24 PPJ DD261019, 20/03/73 MI 1.0 Tis 0.5 ML6-15 MSK Gen</p> <p>CAESAREAN SCAR DEEPEST</p>  <p>1 L 19.30 mm</p> <p>FR 16 AO% 100 CHI Frq 12.0 Gn 46 S/A 3/3 Map F/0 D 5.0 DR 69</p>	<p>NEWCASTLE CLINIC 26/10/19 10:06:42 PPJ DD261019, 20/03/73 MI 1.0 Tis 0.5 ML6-15 MSK Gen</p> <p>CAESAREAN SCAR POST TREATMENT DEEPEST</p>  <p>1 L 10.70 mm</p> <p>FR 16 AO% 100 CHI Frq 12.0 Gn 46 S/A 3/3 Map F/0 D 5.0 DR 69</p>
longitudinal	<p>NEWCASTLE CLINIC 26/10/19 09:42:55 PPJ DD261019, 20/03/73 MI 1.0 Tis 0.5 ML6-15 MSK Gen</p> <p>CAESAREAN SCAR</p>  <p>1 L 9.90 mm</p> <p>FR 16 AO% 100 CHI Frq 12.0 Gn 46 S/A 3/3 Map F/0 D 5.0 DR 69</p>	<p>NEWCASTLE CLINIC 26/10/19 10:10:14 PPJ DD261019, 20/03/73 MI 1.0 Tis 0.5 ML6-15 MSK Gen</p> <p>CAESAREAN SCAR POST TREATMENT</p>  <p>1 L 6.70 mm</p> <p>FR 16 AO% 100 CHI Frq 12.0 Gn 46 S/A 3/3 Map F/0 D 5.0 DR 69</p>
deep	<p>NEWCASTLE CLINIC 26/10/19 09:41:25 PPJ DD261019, 20/03/73 MI 1.0 Tis 0.5 ML6-15 MSK Gen</p> <p>CAESAREAN SCAR DEEP</p>  <p>1 L 16.60 mm</p> <p>FR 16 AO% 100 CHI Frq 12.0 Gn 46 S/A 3/3 Map F/0 D 5.0 DR 69</p>	<p>NEWCASTLE CLINIC 26/10/19 10:07:45 PPJ DD261019, 20/03/73 MI 1.0 Tis 0.5 ML6-15 MSK Gen</p> <p>CAESAREAN SCAR POST TREATMENT DEEP</p>  <p>1 L 3.60 mm</p> <p>FR 16 AO% 100 CHI Frq 12.0 Gn 46 S/A 3/3 Map F/0 D 5.0 DR 69</p>
transverse	<p>NEWCASTLE CLINIC 26/10/19 09:46:29 PPJ DD261019, 20/03/73 MI 1.0 Tis 0.5 ML6-15 MSK Gen</p> <p>CAESAREAN SCAR</p>  <p>1 L 9.90 mm</p> <p>FR 16 AO% 100 CHI Frq 12.0 Gn 46 S/A 3/3 Map F/0 D 5.0 DR 69</p>	<p>NEWCASTLE CLINIC 26/10/19 10:09:30 PPJ DD261019, 20/03/73 MI 1.0 Tis 0.5 ML6-15 MSK Gen</p> <p>CAESAREAN SCAR POST TREATMENT</p>  <p>1 L 7.30 mm</p> <p>FR 16 AO% 100 CHI Frq 12.0 Gn 46 S/A 3/3 Map F/0 D 5.0 DR 69</p>
vascularity	<p>NEWCASTLE CLINIC 26/10/19 09:46:29 PPJ DD261019, 20/03/73 MI 0.8 Tis 1.0 ML6-15 MSK Gen</p> <p>CAESAREAN SCAR</p>  <p>FR 3 AO% 100 CHI Frq 12.0 Gn 46 D 7.0 PDI Frq 7.7 Gn 28.0 L/A 2/5 PRF 1.0 WF 131 S/P 1/16</p>	<p>NEWCASTLE CLINIC 26/10/19 10:14:16 PPJ DD261019, 20/03/73 MI 0.8 Tis 0.9 ML6-15 MSK Gen</p> <p>CAESAREAN SCAR POST TREATMENT</p>  <p>FR 4 AO% 100 CHI Frq 12.0 Gn 46 D 5.0 PDI Frq 7.7 Gn 24.0 L/A 2/5 PRF 0.4 WF 52 S/P 1/16</p>

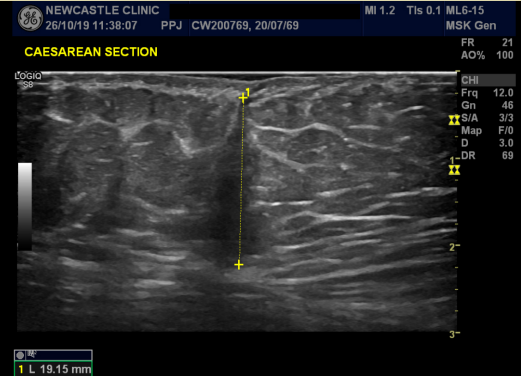
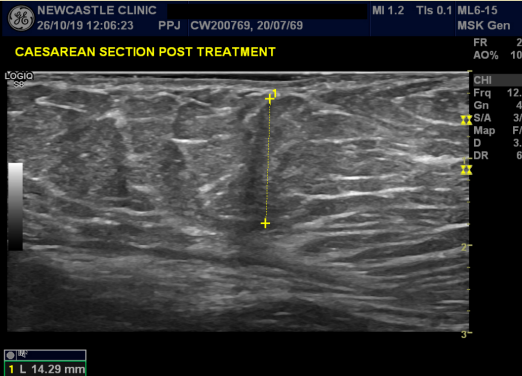
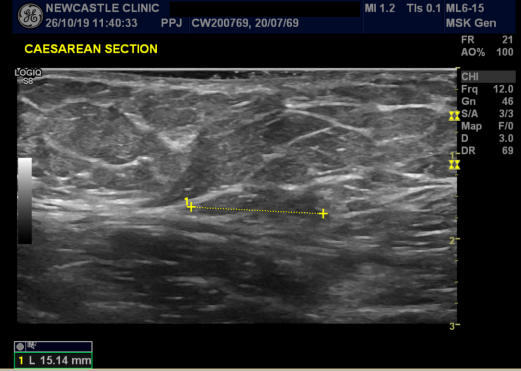
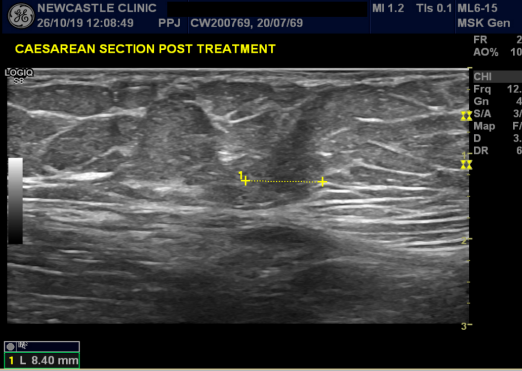
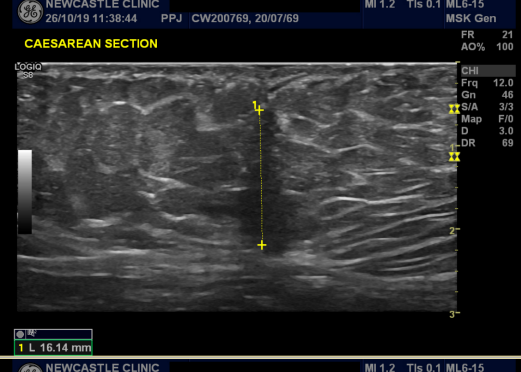

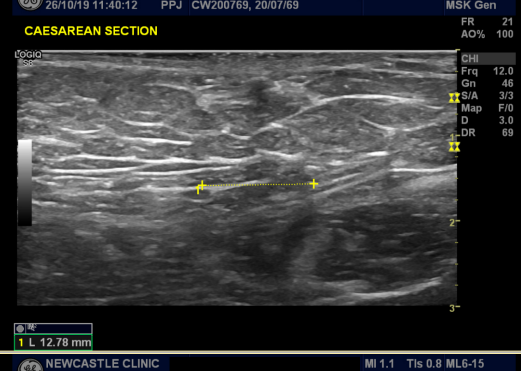
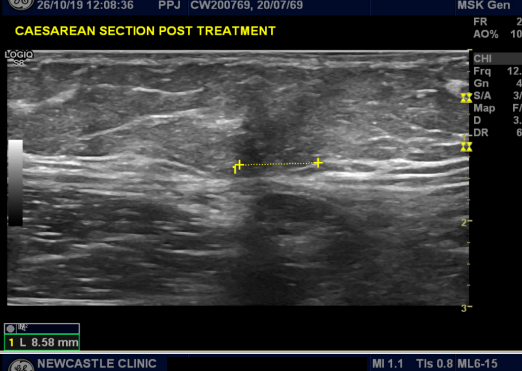
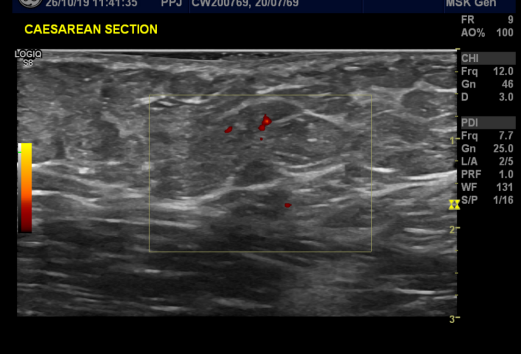
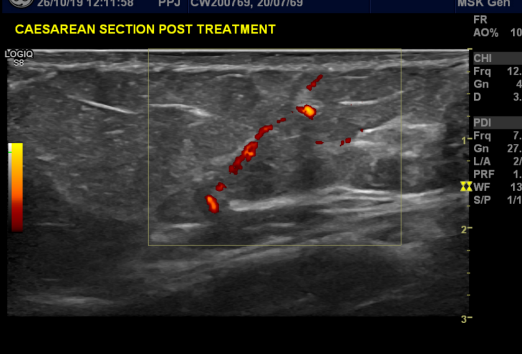
Subject LF	Pre treatment	Post treatment
deepest	 <p>NEWCASTLE CLINIC 26/10/19 14:56:19 PPJ LF250782, 25/07/82 MI 1.2 Tis 0.1 ML6-15 MSK Gen FR 21 AO% 100 CAESAREAN SECTION SCAR CHI Frq 12.0 Gn 46 S/A 3/3 Map F/0 D 3.0 DR 69 1 L 14.21 mm</p>	 <p>NEWCASTLE CLINIC 26/10/19 15:24:58 PPJ LF250782, 25/07/82 MI 1.2 Tis 0.1 ML6-15 MSK Gen FR 21 AO% 100 CAESAREAN SECTION POST TREATMENT CHI Frq 12.0 Gn 46 S/A 3/3 Map F/0 D 3.0 DR 69 1 L 7.26 mm</p>
longitudinal	 <p>NEWCASTLE CLINIC 26/10/19 14:57:15 PPJ LF250782, 25/07/82 MI 1.2 Tis 0.1 ML6-15 MSK Gen FR 21 AO% 100 CAESAREAN SECTION SCAR CHI Frq 12.0 Gn 46 S/A 3/3 Map F/0 D 3.0 DR 69 1 L 9.72 mm 2 L 10.03 mm</p>	 <p>NEWCASTLE CLINIC 26/10/19 15:26:22 PPJ LF250782, 25/07/82 MI 1.2 Tis 0.1 ML6-15 MSK Gen FR 21 AO% 100 CAESAREAN SECTION POST TREATMENT CHI Frq 12.0 Gn 46 S/A 3/3 Map F/0 D 3.0 DR 69 1 L 5.28 mm</p>
deep	 <p>NEWCASTLE CLINIC 26/10/19 14:56:37 PPJ LF250782, 25/07/82 MI 1.2 Tis 0.1 ML6-15 MSK Gen FR 21 AO% 100 CAESAREAN SECTION SCAR CHI Frq 12.0 Gn 46 S/A 3/3 Map F/0 D 3.0 DR 69 1 L 11.95 mm</p>	 <p>NEWCASTLE CLINIC 26/10/19 15:25:38 PPJ LF250782, 25/07/82 MI 1.2 Tis 0.1 ML6-15 MSK Gen FR 21 AO% 100 CAESAREAN SECTION POST TREATMENT CHI Frq 12.0 Gn 46 S/A 3/3 Map F/0 D 3.0 DR 69 1 L 5.11 mm</p>
transverse	 <p>NEWCASTLE CLINIC 26/10/19 14:57:15 PPJ LF250782, 25/07/82 MI 1.2 Tis 0.1 ML6-15 MSK Gen FR 21 AO% 100 CAESAREAN SECTION SCAR CHI Frq 12.0 Gn 46 S/A 3/3 Map F/0 D 3.0 DR 69 1 L 9.72 mm 2 L 10.03 mm</p>	 <p>NEWCASTLE CLINIC 26/10/19 15:26:07 PPJ LF250782, 25/07/82 MI 1.2 Tis 0.1 ML6-15 MSK Gen FR 21 AO% 100 CAESAREAN SECTION POST TREATMENT CHI Frq 12.0 Gn 46 S/A 3/3 Map F/0 D 3.0 DR 69 1 L 5.71 mm</p>
vascularity	 <p>NEWCASTLE CLINIC 26/10/19 14:59:53 PPJ LF250782, 25/07/82 MI 1.1 Tis 0.7 ML6-15 MSK Gen FR 9 AO% 100 CAESAREAN SECTION SCAR CHI Frq 12.0 Gn 46 D 3.0 PDI 7.7 Frq 25.0 L/A 2/5 PRF 1.0 WF 131 S/P 1/16</p>	 <p>NEWCASTLE CLINIC 26/10/19 15:28:43 PPJ LF250782, 25/07/82 MI 1.1 Tis 0.8 ML6-15 MSK Gen FR 9 AO% 100 CAESAREAN SECTION POST TREATMENT CHI Frq 12.0 Gn 46 D 3.0 PDI 7.7 Frq 25.0 L/A 2/5 PRF 1.0 WF 130 S/P 1/16</p>



Subject NC	Pre treatment	Post treatment
deepest	<p>NEWCASTLE CLINIC 26/10/19 10:22:48 PPJ NC120970, 12/09/70 MI 1.1 Tis 0.1 ML6-15 MSK Gen</p> <p>HYSTERECTOMY SCAR DEEPEST</p> <p>1 L 11.35 mm</p> <p>FR 21 AO% 100</p> <p>CHI 12.0 Frq 46 Gn 3/3 S/A F/0 Map 3.3 D 69 1-DR</p>	<p>NEWCASTLE CLINIC 26/10/19 10:49:52 PPJ NC120970, 12/09/70 MI 1.2 Tis 0.1 ML6-15 MSK Gen</p> <p>HYSTERECTOMY SCAR POST TREATMENT</p> <p>1 L 9.95 mm</p> <p>FR 22 AO% 100</p> <p>CHI 12.0 Frq 46 Gn 3/3 S/A F/0 Map 2.5 D 69 1-DR</p>
longitudinal	<p>NEWCASTLE CLINIC 26/10/19 10:24:45 PPJ NC120970, 12/09/70 MI 1.1 Tis 0.1 ML6-15 MSK Gen</p> <p>HYSTERECTOMY SCAR LONG</p> <p>1 L 7.20 mm 2 L 6.73 mm</p> <p>FR 21 AO% 100</p> <p>CHI 12.0 Frq 46 Gn 3/3 S/A F/0 Map 3.3 D 69 1-DR</p>	<p>NEWCASTLE CLINIC 26/10/19 10:52:47 PPJ NC120970, 12/09/70 MI 1.2 Tis 0.1 ML6-15 MSK Gen</p> <p>HYSTERECTOMY SCAR POST TREATMENT</p> <p>1 L 4.65 mm 2 L 6.55 mm</p> <p>FR 22 AO% 100</p> <p>CHI 12.0 Frq 46 Gn 3/3 S/A F/0 Map 2.5 D 69 1-DR</p>
deep	<p>NEWCASTLE CLINIC 26/10/19 10:23:29 PPJ NC120970, 12/09/70 MI 1.1 Tis 0.1 ML6-15 MSK Gen</p> <p>HYSTERECTOMY SCAR DEEP</p> <p>1 L 11.22 mm</p> <p>FR 21 AO% 100</p> <p>CHI 12.0 Frq 46 Gn 3/3 S/A F/0 Map 3.3 D 69 1-DR</p>	<p>NEWCASTLE CLINIC 26/10/19 10:52:01 PPJ NC120970, 12/09/70 MI 1.2 Tis 0.1 ML6-15 MSK Gen</p> <p>HYSTERECTOMY SCAR POST TREATMENT</p> <p>1 L 5.13 mm</p> <p>FR 22 AO% 100</p> <p>CHI 12.0 Frq 46 Gn 3/3 S/A F/0 Map 2.5 D 69 1-DR</p>
transverse	<p>NEWCASTLE CLINIC 26/10/19 10:24:45 PPJ NC120970, 12/09/70 MI 1.1 Tis 0.1 ML6-15 MSK Gen</p> <p>HYSTERECTOMY SCAR TRANSV</p> <p>1 L 7.20 mm</p> <p>FR 21 AO% 100</p> <p>CHI 12.0 Frq 46 Gn 3/3 S/A F/0 Map 3.3 D 69 1-DR</p>	<p>NEWCASTLE CLINIC 26/10/19 10:52:47 PPJ NC120970, 12/09/70 MI 1.2 Tis 0.1 ML6-15 MSK Gen</p> <p>HYSTERECTOMY SCAR POST TREATMENT</p> <p>1 L 4.65 mm</p> <p>FR 22 AO% 100</p> <p>CHI 12.0 Frq 46 Gn 3/3 S/A F/0 Map 2.5 D 69 1-DR</p>
vascularity	<p>NEWCASTLE CLINIC 26/10/19 10:28:10 PPJ NC120970, 12/09/70 MI 1.0 Tis 0.8 ML6-15 MSK Gen</p> <p>HYSTERECTOMY SCAR VASC</p> <p>FR 8 AO% 100</p> <p>CHI 12.0 Frq 46 Gn 3.3 D 69 1-DR</p> <p>PDI 7.7 Frq 25.0 Gn 2/5 L/A 1.0 PRF 131 WF 1/16 S/P</p>	<p>NEWCASTLE CLINIC 26/10/19 10:55:11 PPJ NC120970, 12/09/70 MI 1.1 Tis 0.8 ML6-15 MSK Gen</p> <p>HYSTERECTOMY SCAR POST TREATMENT</p> <p>FR 8 AO% 100</p> <p>CHI 12.0 Frq 46 Gn 2.5 D 69 1-DR</p> <p>PDI 7.7 Frq 25.0 Gn 2/5 L/A 1.0 PRF 131 WF 1/16 S/P</p>

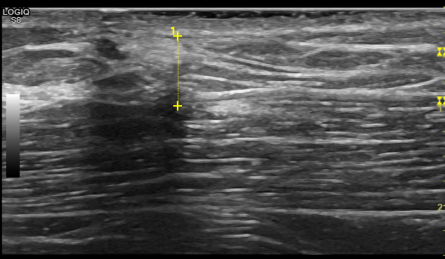
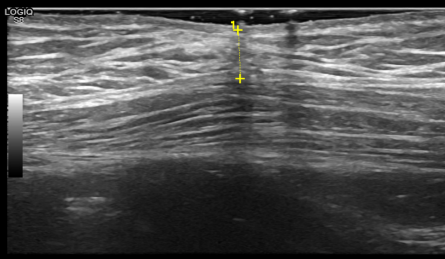
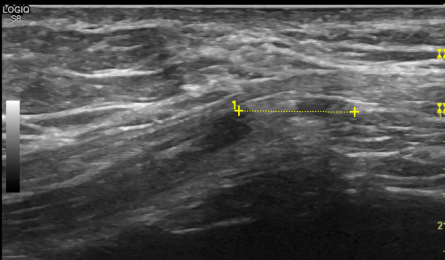
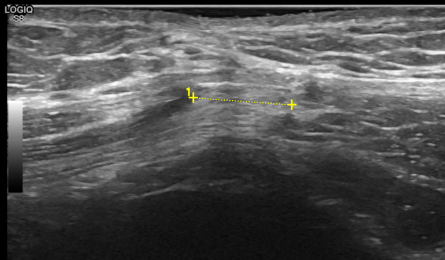
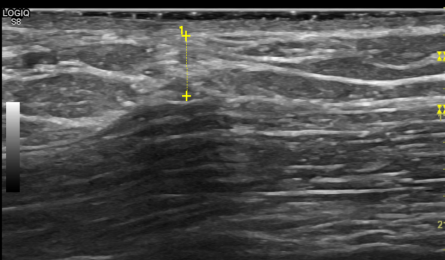
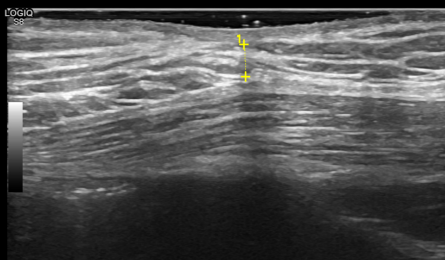
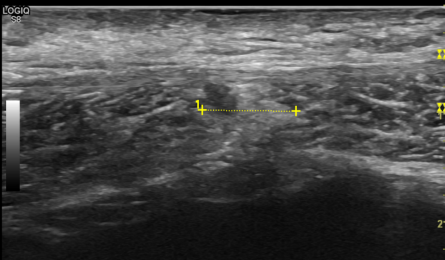
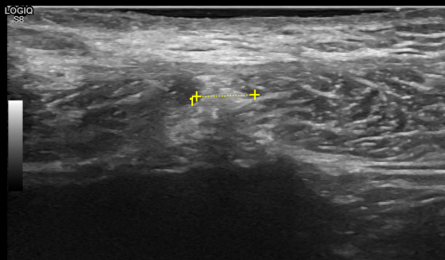
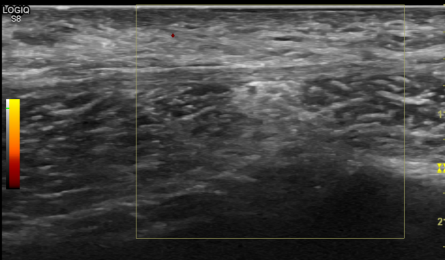
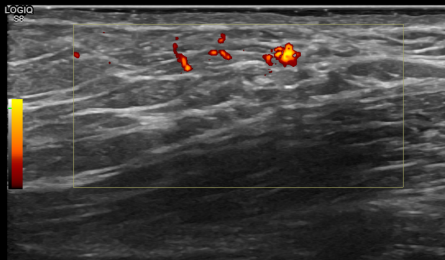
Subject PE	Pre treatment	Post treatment
deepest	NO IMAGE RECORDED	NO IMAGE RECORDED
longitudinal	 <p>NEWCASTLE CLINIC 26/10/19 11:16:33 PPJ PE170170, 17/01/70 MI 1.1 TIs 0.1 ML6-15 MSK Gen CAESAREAN SECTION SCAR LOGIO S8 1 L 18.42 mm FR 20 AO% 100 CHI Frq 12.0 Gn 46 S/A 3/3 Map F/0 D 3.5 1- DR 69 2- 3-</p>	 <p>NEWCASTLE CLINIC 26/10/19 11:27:57 PPJ PE170170, 17/01/70 MI 1.0 TIs 0.9 ML6-15 MSK Gen CAESAREAN SECTION SCAR LOGIO S8 1 L 8.81 mm FR 6 AO% 100 CHI Frq 12.0 Gn 46 D 3.5 1- PDI Frq 7.7 Gn 25.0 L/A 2/5 PRF 1.0 WF 131 S/P 1/16 2- 3-</p>
deep	NO IMAGE RECORDED	NO IMAGE RECORDED
transverse	 <p>NEWCASTLE CLINIC 26/10/19 11:16:53 PPJ PE170170, 17/01/70 MI 1.1 TIs 0.1 ML6-15 MSK Gen CAESAREAN SECTION SCAR LOGIO S8 1 L 14.97 mm FR 20 AO% 100 CHI Frq 12.0 Gn 46 S/A 3/3 Map F/0 D 3.5 1- DR 69 2- 3-</p>	 <p>NEWCASTLE CLINIC 26/10/19 11:28:45 PPJ PE170170, 17/01/70 MI 1.0 TIs 0.9 ML6-15 MSK Gen CAESAREAN SECTION SCAR LOGIO S8 1 L 11.34 mm FR 6 AO% 100 CHI Frq 12.0 Gn 46 D 3.5 1- PDI Frq 7.7 Gn 25.0 L/A 2/5 PRF 1.0 WF 131 S/P 1/16 2- 3-</p>
vascularity	 <p>NEWCASTLE CLINIC 26/10/19 11:17:35 PPJ PE170170, 17/01/70 MI 1.0 TIs 0.9 ML6-15 MSK Gen CAESAREAN SECTION SCAR LOGIO S8 1 L 11.73 mm FR 6 AO% 100 CHI Frq 12.0 Gn 46 D 3.5 1- PDI Frq 7.7 Gn 25.0 L/A 2/5 PRF 1.0 WF 131 S/P 1/16 2- 3-</p>	 <p>NEWCASTLE CLINIC 26/10/19 11:29:08 PPJ PE170170, 17/01/70 MI 1.0 TIs 0.9 ML6-15 MSK Gen CAESAREAN SECTION SCAR LOGIO S8 1 L 11.34 mm FR 6 AO% 100 CHI Frq 12.0 Gn 46 D 3.5 1- PDI Frq 7.7 Gn 25.0 L/A 2/5 PRF 1.0 WF 131 S/P 1/16 2- 3-</p>



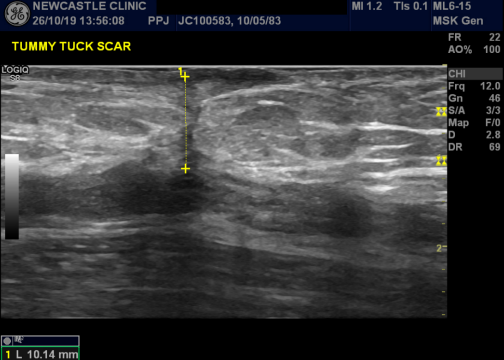
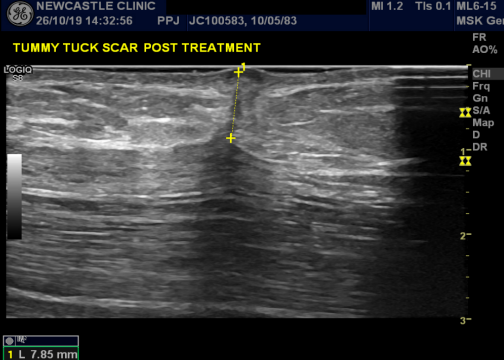
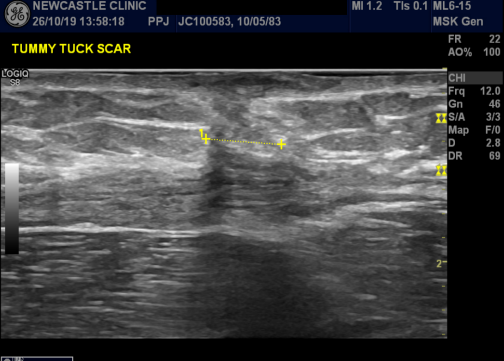
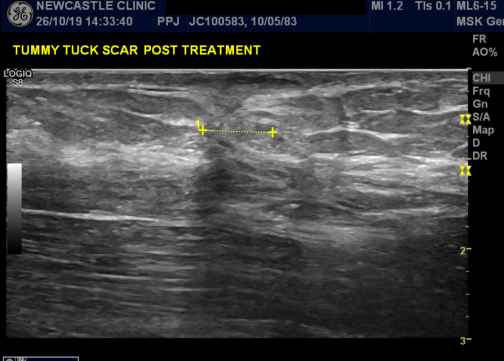
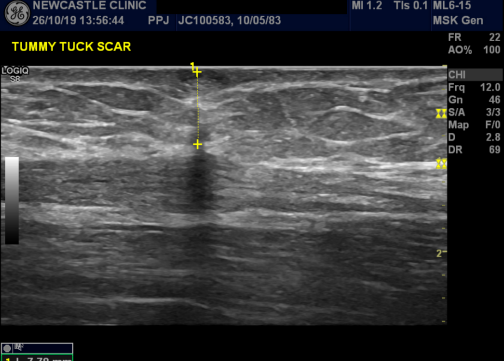
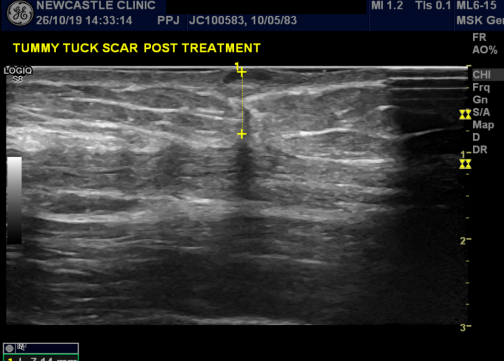
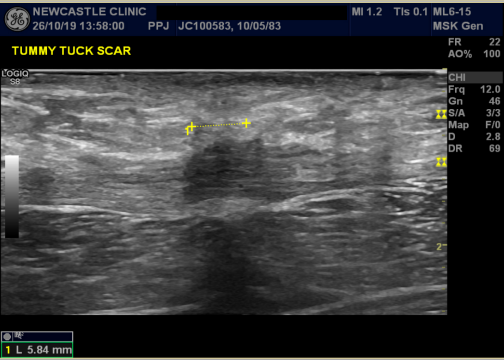
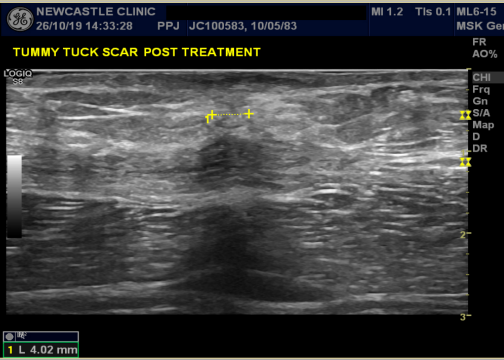
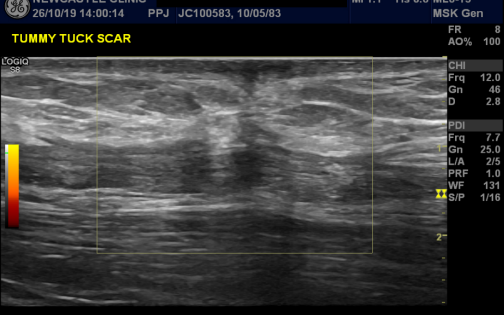
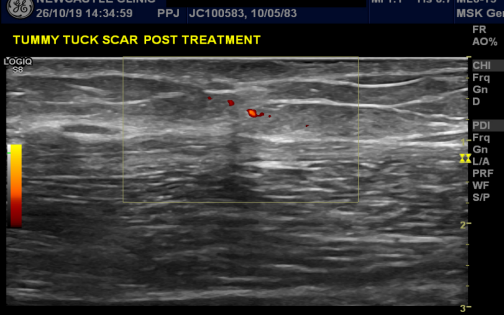
Subject CW	Pre treatment	Post treatment
deepest		
longitudinal		
deep		
transverse		
vascularity		

Subject AB	Pre treatment	Post treatment
deepest	<p>NEWCASTLE CLINIC 26/10/19 11:58:28 PPJ AB1210566, 12/05/66 MI 1.1 Tis 0.1 ML6-15 MSK Gen</p> <p>CAESAREAN SECTION SCAR</p> <p>1 L 17.12 mm</p> <p>FR 20 AO% 100</p> <p>CHI Frq 12.0 Gn 46 S/A 3/3 Map F/0 D 3.5 DR 69</p>	<p>NEWCASTLE CLINIC 26/10/19 12:24:54 PPJ AB1210566, 12/05/66 MI 1.2 Tis 0.1 ML6-15 MSK Gen</p> <p>SCAR POST TREATMENT</p> <p>1 L 15.79 mm</p> <p>FR 21 AO% 100</p> <p>CHI Frq 12.0 Gn 46 S/A 3/3 Map F/0 D 3.0 DR 69</p>
longitudinal	<p>NEWCASTLE CLINIC 26/10/19 12:00:43 PPJ AB1210566, 12/05/66 MI 1.1 Tis 0.1 ML6-15 MSK Gen</p> <p>CAESAREAN SECTION SCAR</p> <p>1 L 14.28 mm</p> <p>FR 20 AO% 100</p> <p>CHI Frq 12.0 Gn 46 S/A 3/3 Map F/0 D 3.5 DR 69</p>	<p>NEWCASTLE CLINIC 26/10/19 12:27:31 PPJ AB1210566, 12/05/66 MI 1.2 Tis 0.1 ML6-15 MSK Gen</p> <p>SCAR POST TREATMENT</p> <p>1 L 8.25 mm</p> <p>FR 21 AO% 100</p> <p>CHI Frq 12.0 Gn 46 S/A 3/3 Map F/0 D 3.0 DR 69</p>
deep	<p>NEWCASTLE CLINIC 26/10/19 11:59:41 PPJ AB1210566, 12/05/66 MI 1.1 Tis 0.1 ML6-15 MSK Gen</p> <p>CAESAREAN SECTION SCAR</p> <p>1 L 10.99 mm</p> <p>FR 20 AO% 100</p> <p>CHI Frq 12.0 Gn 46 S/A 3/3 Map F/0 D 3.5 DR 69</p>	<p>NEWCASTLE CLINIC 26/10/19 12:26:16 PPJ AB1210566, 12/05/66 MI 1.2 Tis 0.1 ML6-15 MSK Gen</p> <p>SCAR POST TREATMENT</p> <p>1 L 9.00 mm</p> <p>FR 21 AO% 100</p> <p>CHI Frq 12.0 Gn 46 S/A 3/3 Map F/0 D 3.0 DR 69</p>
transverse	<p>NEWCASTLE CLINIC 26/10/19 12:00:15 PPJ AB1210566, 12/05/66 MI 1.1 Tis 0.1 ML6-15 MSK Gen</p> <p>CAESAREAN SECTION SCAR</p> <p>1 L 13.52 mm</p> <p>FR 20 AO% 100</p> <p>CHI Frq 12.0 Gn 46 S/A 3/3 Map F/0 D 3.5 DR 69</p>	<p>NEWCASTLE CLINIC 26/10/19 12:26:58 PPJ AB1210566, 12/05/66 MI 1.2 Tis 0.1 ML6-15 MSK Gen</p> <p>SCAR POST TREATMENT</p> <p>1 L 11.77 mm</p> <p>FR 21 AO% 100</p> <p>CHI Frq 12.0 Gn 46 S/A 3/3 Map F/0 D 3.0 DR 69</p>
vascularity	<p>NEWCASTLE CLINIC 26/10/19 12:02:10 PPJ AB1210566, 12/05/66 MI 1.0 Tis 0.9 ML6-15 MSK Gen</p> <p>CAESAREAN SECTION SCAR</p> <p>FR 7 AO% 100</p> <p>CHI Frq 12.0 Gn 46 D 3.5</p> <p>PDI Frq 7.7 Gn 25.0 L/A 2/5 PRF 1.0 WF 131 S/P 1/16</p>	<p>NEWCASTLE CLINIC 26/10/19 12:28:26 PPJ AB1210566, 12/05/66 MI 1.1 Tis 0.8 ML6-15 MSK Gen</p> <p>SCAR POST TREATMENT</p> <p>FR 8 AO% 100</p> <p>CHI Frq 12.0 Gn 46 D 3.0</p> <p>PDI Frq 7.7 Gn 25.0 L/A 2/5 PRF 1.0 WF 131 S/P 1/16</p>



Subject KH	Pre treatment	Post treatment
deepest	<p>NEWCASTLE CLINIC 26/10/19 13:45:13 PPJ KH100977, 10/09/77 MI 1.2 TIs 0.1 ML6-15 MSK Gen FR 22 AO% 100</p> <p>CAESAREAN SECTION SCAR</p>  <p>CHI 12.0 Frq 46 Gn 46 S/A 3/3 Map F/0 D 2.5 DR 69</p> <p>1 L 7.05 mm</p>	<p>NEWCASTLE CLINIC 26/10/19 14:14:47 PPJ KH100977, 10/09/77 MI 1.2 TIs 0.1 ML6-15 MSK Gen FR 21 AO% 100</p> <p>POST TREATMENT SCAR</p>  <p>CHI 12.0 Frq 46 Gn 46 S/A 3/3 Map F/0 D 3.0 DR 69</p> <p>1 L 5.88 mm</p>
longitudinal	<p>NEWCASTLE CLINIC 26/10/19 13:49:36 PPJ KH100977, 10/09/77 MI 1.2 TIs 0.1 ML6-15 MSK Gen FR 22 AO% 100</p> <p>CAESAREAN SECTION SCAR</p>  <p>CHI 12.0 Frq 46 Gn 46 S/A 3/3 Map F/0 D 2.5 DR 69</p> <p>1 L 11.05 mm</p>	<p>NEWCASTLE CLINIC 26/10/19 14:16:07 PPJ KH100977, 10/09/77 MI 1.2 TIs 0.1 ML6-15 MSK Gen FR 21 AO% 100</p> <p>POST TREATMENT SCAR</p>  <p>CHI 12.0 Frq 46 Gn 46 S/A 3/3 Map F/0 D 3.0 DR 69</p> <p>1 L 10.77 mm</p>
deep	<p>NEWCASTLE CLINIC 26/10/19 13:46:08 PPJ KH100977, 10/09/77 MI 1.2 TIs 0.1 ML6-15 MSK Gen FR 22 AO% 100</p> <p>CAESAREAN SECTION SCAR</p>  <p>CHI 12.0 Frq 46 Gn 46 S/A 3/3 Map F/0 D 2.5 DR 69</p> <p>1 L 5.60 mm</p>	<p>NEWCASTLE CLINIC 26/10/19 14:15:10 PPJ KH100977, 10/09/77 MI 1.2 TIs 0.1 ML6-15 MSK Gen FR 21 AO% 100</p> <p>POST TREATMENT SCAR</p>  <p>CHI 12.0 Frq 46 Gn 46 S/A 3/3 Map F/0 D 3.0 DR 69</p> <p>1 L 3.60 mm</p>
transverse	<p>NEWCASTLE CLINIC 26/10/19 13:49:54 PPJ KH100977, 10/09/77 MI 1.2 TIs 0.1 ML6-15 MSK Gen FR 22 AO% 100</p> <p>CAESAREAN SECTION SCAR</p>  <p>CHI 12.0 Frq 46 Gn 46 S/A 3/3 Map F/0 D 2.5 DR 69</p> <p>1 L 8.95 mm</p>	<p>NEWCASTLE CLINIC 26/10/19 14:15:36 PPJ KH100977, 10/09/77 MI 1.2 TIs 0.1 ML6-15 MSK Gen FR 21 AO% 100</p> <p>POST TREATMENT SCAR</p>  <p>CHI 12.0 Frq 46 Gn 46 S/A 3/3 Map F/0 D 3.0 DR 69</p> <p>1 L 6.36 mm</p>
vascularity	<p>NEWCASTLE CLINIC 26/10/19 13:50:40 PPJ KH100977, 10/09/77 MI 1.1 TIs 0.8 ML6-15 MSK Gen FR 9 AO% 100</p> <p>CAESAREAN SECTION SCAR</p>  <p>CHI 12.0 Frq 46 Gn 46 D 2.5 PDI 7.7 Frq 25.0 L/A 2/5 PRF 1.0 WF 131 S/P 1/16</p> <p>1 L 8.95 mm</p>	<p>NEWCASTLE CLINIC 26/10/19 14:19:04 PPJ KH100977, 10/09/77 MI 1.1 TIs 0.8 ML6-15 MSK Gen FR 7 AO% 100</p> <p>POST TREATMENT SCAR</p>  <p>CHI 12.0 Frq 46 D 3.0 PDI 7.7 Frq 25.0 L/A 2/5 PRF 1.0 WF 131 S/P 1/16</p> <p>1 L 6.36 mm</p>



Subject JC		Pre treatment	Post treatment
deepest			
longitudinal			
deep			
transverse			
vascularity			

Subject SS	Pre treatment	Post treatment
deepest		
longitudinal		
deep		
transverse		
vascularity		

Total length of all scars measured pre-treatment = 379.21mm

Total length of all scars measured post-treatment = 260.81mm

Total reduction in all scar tissue measured = 31.22%

## **Conclusion**

After a single 15 minute MSTR® treatment per subject and an immediate rescan of the area there was an observable reduction in the amount of scar tissue measured for the nine subjects.

The total reduction of scar tissue is calculated at 31.22% which is a significant improvement and demonstrates that MSTR® reduces scar tissue in a single treatment.

The results of this research also reinforce previous research findings (June 2019) where the total reduction of scars was measured at 33.55%. This second study now demonstrates the consistently high and reliable scar tissue response rates with MSTR® treatment.

Alastair McLoughlin  
[www.McLoughlin-Scar-Release.com](http://www.McLoughlin-Scar-Release.com)

---

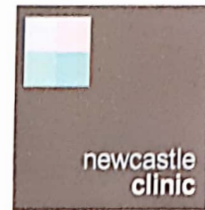© Alastair McLoughlin

Below are the reports from The Newcastle Clinic, prepared by Dr Peddada Raju of The Newcastle Clinic - UK, dated October 30th, 2019.

Ref: PPJR/SR

Scan Date: 26.10.19

30<sup>th</sup> October 2019



Mr Alastair McLoughlin

Germany

Dear Mr McLoughlin

Re:           D       D                   DOB: 20.03.73

**Ultrasound Examination – Anterior abdominal wall**

**Clinical Details:** History of caesarean section scar in the lower abdominal wall.

**Report:** The anterior abdominal wall scar in the subcutaneous fat was barely visible and was difficult to measure. The approximate deepest dimension of the scar before treatment is 19.3mm but after the treatment decreased to 10.7mm.

The approximate depth of the scar which was measured just right of the midline (right lateral) was approximately 16.6mm before treatment but after treatment the approximate depth just right of midline decreased to approximately 3.6mm.

The approximate dimensions of the scar in longitudinal and transverse dimensions is 9.4mm x 9.9mm respectively before treatment but following treatment the scar tissue measures approximately 6.7mm x 7.3mm in maximum approximate longitudinal and transverse dimensions respectively.

There was no evidence of any vascularity noted in the scar or around the scar before treatment but following treatment, blood supply around the scar was noted especially in the subcutaneous adipose tissue but there was no evidence of any vascularity noted in the scar following treatment.

Yours sincerely

**Dr. P P J Raju**  
**Consultant Radiologist**

Newcastle Clinic Limited  
4 Towers Avenue  
Jesmond  
Newcastle Upon Tyne  
NE2 3QE

t: 0191 281 2636  
f: 0191 281 2393

reception@newcastleclinic.co.uk

Registered by the Care Quality Commission No: NO10000008

Company Registration Number: 5843596


Registered Office: Oakapple House, 1 John Charles Way, Leeds, LS12 6QA



Ref: PPJR/SR

Scan Date: 26.10.19

30<sup>th</sup> October 2019



Mr Alastair McLoughlin

Germany

Dear Mr McLoughlin

Re: P E DOB: 17.01.70

**Ultrasound Examination – Anterior abdominal wall**

**Clinical Details:** Caesarean section noted.

**Report:** On ultrasound examination, scar tissue measures approximately 18.4mm x 14.9mm in maximum approximate longitudinal and transverse dimensions respectively before treatment but following treatment, there was a decrease in the dimensions of the scar tissue. The scar tissue measures approximately 8.8mm x 11.3mm in maximum longitudinal and transverse dimensions respectively.

Before treatment, there was no evidence of any vascularity noted in and around the scar but following treatment, there was vascularity noted around the scar in the anterior fascia covering the anterior aspect of the rectus abdominus muscle.

Yours sincerely

**Dr. P P J Raju**  
**Consultant Radiologist**

Newcastle Clinic Limited  
4 Towers Avenue  
Jesmond  
Newcastle Upon Tyne  
NE2 3QE  
t: 0191 281 2636  
f: 0191 281 2393  
reception@newcastleclinic.co.uk

Registered by the Care Quality Commission No: NO1000008  
Company Registration Number: 5843596  
Registered Office: Oakapple House, 1 John Charles Way, Leeds, LS12 6QA

Ref: PPJR/SR

Scan Date: 26.10.19

30<sup>th</sup> October 2019



Mr Alastair McLoughlin

Germany

Dear Mr McLoughlin

**Re: C W DOB: 20.07.69**

**Ultrasound Examination – Anterior abdominal wall**

**Clinical Details:** Caesarean section noted.

**Report:** There is evidence of lower abdominal wall caesarean section scar. The deepest dimensions of the anterior abdominal wall scar in the region of the caesarean section measures approximately 19.5mm before treatment but following treatment, the deepest dimension of the scar decreased to approximately 14.2mm only. The approximate depth of the scar before treatment was 16.1mm especially to the right of the midline but following treatment, the approximate depth of the scar decreased to 10.6mm. Approximate dimensions of the scar are 15.1mm x 12.7mm in maximum longitudinal and transverse dimensions respectively before treatment but following treatment, the approximate dimensions of the scar are 8.4mm x 8.5mm in maximum longitudinal and transverse dimensions respectively. On power Doppler interrogation there was minimal vascularity noted around the scar, but no evidence of any vascularity in the scar tissue. Following treatment, there was increase in the vascularity around the scar tissue but again, no evidence of any abnormal vascularity noted in the scar tissue following treatment.

Yours sincerely

**Dr. P P J Raju**  
**Consultant Radiologist**

Newcastle Clinic Limited  
4 Towers Avenue  
Jesmond  
Newcastle Upon Tyne  
NE2 3QE

t: 0191 281 2636  
f: 0191 281 2393

reception@newcastleclinic.co.uk

Registered by the Care Quality Commission No: NO10000008

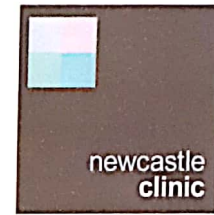
Company Registration Number: 5843596

Registered Office: Oakapple House, 1 John Charles Way, Leeds, LS12 6QA

Ref: PPJR/SR

Scan Date: 26.10.19

30<sup>th</sup> October 2019



Mr Alastair McLoughlin

Germany

Dear Mr McLoughlin

**Re:           A           B           DOB: 12.05.66**

**Ultrasound Examination – Anterior abdominal wall**

**Clinical Details:** Caesarean section noted.

**Report:** There is evidence of healed scar noted in the suprapubic region in the lower abdominal wall related to healed caesarean section scar.

Approximately deepest dimension of the scar before treatment is 17mm which decreased to 15.7mm following treatment. The depth of the scar just right of midline is approximately 10.9mm which decreased to 9mm following treatment.

Approximate dimensions of the scar are 14.2mm x 13.5mm and maximum longitudinal and transverse dimension respectively before treatment but following treatment, the approximate dimensions are 8.2mm x 11mm and maximum longitudinal and transverse dimensions respectively.

There was no evidence of any vascularity noted around the scar before treatment but following treatment, there was evidence of minimal vascularity noted in the scar and around the scar on power Doppler interrogation.

Yours sincerely

**Dr. P P J Raju**  
**Consultant Radiologist**

Newcastle Clinic Limited  
4 Towers Avenue  
Jesmond  
Newcastle Upon Tyne  
NE2 3QE  
t: 0191 281 2636  
f: 0191 281 2393  
reception@newcastleclinic.co.uk

Registered by the Care Quality Commission No: NO10000008  
Company Registration Number: 5843596  
Registered Office: Oakapple House, 1 John Charles Way, Leeds, LS12 6QA

Ref: PPJR/SR

Scan Date: 26.10.19

30<sup>th</sup> October 2019

Mr Alastair McLoughlin

Germany

Dear Mr McLoughlin

Re:           K           H                   DOB: 10.09.77

**Ultrasound Examination – Anterior abdominal wall**

**Clinical Details:** Caesarean section noted.

**Report:** The deepest dimension of the scar in the midline is approximately 7mm before treatment but following treatment, the deepest dimension of the scar decreased to approximately 5.8mm.

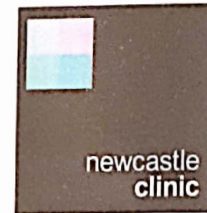The dimension of the scar especially in its maximum depth just right of midline is approximately 5.6mm before treatment but following treatment, this dimension decreased to approximately 3.6mm.

The approximate dimensions of the scar are 8.9mm x 11mm in maximum transverse and longitudinal dimensions respectively before treatment but following treatment, the approximate dimensions of the scar are 6.3mm x 10.7mm and maximum transverse and longitudinal dimensions respectively.

On power Doppler interrogation, there was no evidence of any vascularity noted in the scar or around the scar but following treatment, there was evidence of vascularity noted around the scar including mildly increased vascularity in the scar itself. Please note that this is a deep fascial scar and there was no evidence of any subcutaneous scar tissue especially in the subcutaneous fat on the ultrasound examination.

Yours sincerely

**Dr. P P J Raju**  
**Consultant Radiologist**



Newcastle Clinic Limited  
4 Towers Avenue  
Jesmond  
Newcastle Upon Tyne  
NE2 3QE  
t: 0191 281 2636  
f: 0191 281 2393  
reception@newcastleclinic.co.uk

Registered by the Care Quality Commission No: NO1000008  
Company Registration Number: 5843596  
Registered Office: Oakapple House, 1 John Charles Way, Leeds, LS12 6QA



Ref: PPJR/LE

Scan Date: 26.10.19

5<sup>th</sup> November 2019



Mr Alastair McLoughlin

Germany

Dear Mr McLoughlin

Re: J C D.O.B. 10.05.83

**Ultrasound Examination – Anterior abdominal wall**

**Clinical Details:** Tummy Tuck scar noted.

**Report:** The deepest dimension of the scar is approximately 10 mm before treatment. Treatment and the deepest dimension decreased to approximately 7.8 mm. The approximate dimensions of the scar just right of midline is 7.7 mm in its maximum depth which decreased to approximately 7.1 mm following treatment.

The dimensions of the scar tissue is approximately 8 mm x 5.8 mm in maximum longitudinal and transverse dimensions respectively before treatment.

After treatment, the approximate dimensions of scar are 7.6 mm x 4 mm in maximum longitudinal and transverse dimensions respectively.

Before treatment, there was no evidence of vascularity in the scar tissue and there was no evidence of any vascularity noted around the scar tissue on power Doppler interrogation. Following treatment, there was increased vascularity noted in the scar and around the scar.

Yours sincerely

**Dr. P P J Raju**  
**Consultant Radiologist**

Newcastle Clinic Limited  
4 Towers Avenue  
Jesmond  
Newcastle Upon Tyne  
NE2 3QE

t: 0191 281 2636

f: 0191 281 2393

reception@newcastleclinic.co.uk

Registered by the Care Quality Commission No: NO10000008

Company Registration Number: 5843596

Registered Office: Oakapple House, 1 John Charles Way, Leeds, LS12 6QA

Ref: PPJR/SR

Scan Date: 26.10.19

30<sup>th</sup> October 2019



Mr Alastair McLoughlin

Germany

Dear Mr McLoughlin

**Re:            S        S                    DOB: 13.03.86**

**Ultrasound Examination – Anterior abdominal wall**

**Clinical Details:** Caesarean section noted.

**Report:** Before treatment, the depressed dimension of the scar tissue is approximately 9.3mm which decreased to approximately 7.5mm following treatment of the scar. The approximate dimensions of the scar just right of midline is 6.3mm before treatment but following treatment, the approximate dimensions of the scar is 4.4mm.

The approximate measurements of the scar is 5.3mm x 3.4mm in maximum longitudinal and transverse dimension respectively following treatment, the approximate dimensions of the scar of 4.8mm x 5.7mm in maximum longitudinal and transverse dimensions respectively.

On power Doppler interrogation, there was no evidence of any vascularity noted in and around the scar but following treatment, there was evidence of vascularity noted around the scar which was essentially noted just superficial and anterior to the scar in the subcutaneous soft tissues.

Yours sincerely

**Dr. P P J Raju**  
**Consultant Radiologist**

Newcastle Clinic Limited  
4 Towers Avenue  
Jesmond  
Newcastle Upon Tyne  
NE2 3QE  
t: 0191 281 2636  
f: 0191 281 2393  
reception@newcastleclinic.co.uk

Registered by the Care Quality Commission No. NO1000008  
Company Registration Number: 5843596  
Registered Office: Oakapple House, 1 John Charles Way, Leeds, LS12 6QA

